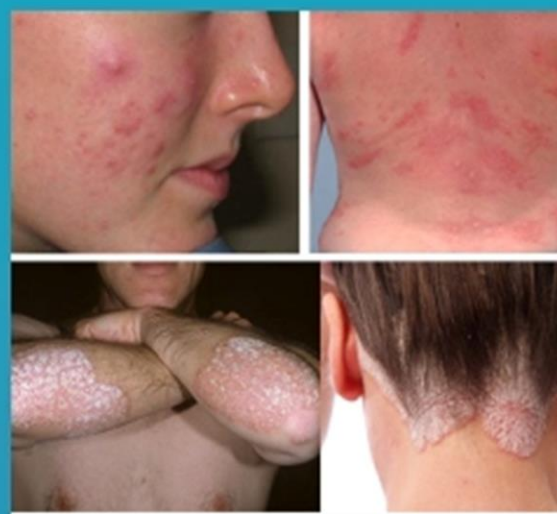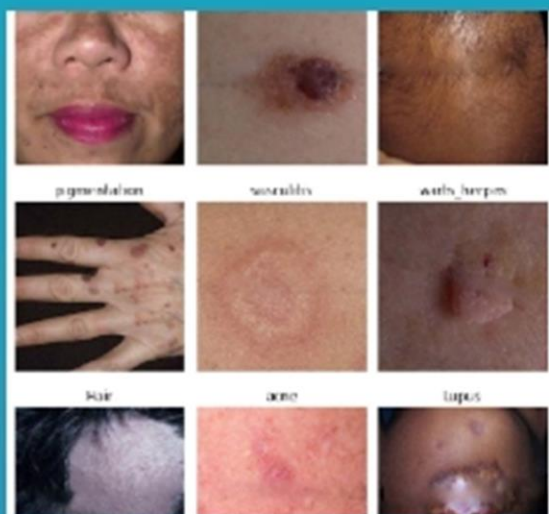


ISSN: 2835-1568 CODEN: USA DOI: 10.51521



WORLD JOURNAL OF CASE REPORTS & CLINICAL IMAGES

Advancing Cases



<https://worldjournalofcasereports.org/>



CASE SERIES

Diagnostic Challenge of d-dimer Negative Upper Extremity DVT

Andrew Ryan¹, Mark Ferguson¹, Mohammed Hassan¹, Aaron Niblock^{1,3}

Received Date:
14-11-2023
Revised Date:
22-11-2023
Accepted Date:
25-11-2023
Published Date:
02-12-2023

¹Antrim Area Hospital, N. Ireland

²Ulster University, School of Medicine, N. Ireland

Abstract

Studies suggest D-Dimer has a high sensitivity with negative predictive value for upper extremity DVT (UEDVT). Sensitivity is around 92% with a negative predictive value of 98%. UEDVT is an uncommon presentation with an incidence rate of 4-10%. Risk factors for UEDVT include thrombophilia, central venous catheters, malignancy, pacemakers and upper limb surgery and/or immobilisation. The use of scoring systems for assessing UEDVT risk is less well known and therefore poorly utilised. A scoring system similar to a Wells' score, known as Constans criteria, is a 2 level scoring system developed and first published in 2008. The Criteria considers, venous material *in-situ*, localised pain, unilateral oedema and plausibility of alternative cause. Score interpretation; -1 to 0 points (low probability of UEDVT 12%), 1 point (intermediate probability 20%), 2 to 3 points (high probability 70%). Kleinjan, *et al.*, sought further improved upon this scoring tool by incorporating D-dimer results in the stratification of intermediate risk patients, asserting that its use can safely and effectively exclude venous thrombosis of the upper extremity. This case series shows 2 patients diagnosed with UEDVT. both patients had a Constans score of 1 therefore prompting use of D-Dimer results to stratify risk. Irrespective of negative D-dimer results, ultrasound doppler scans were performed and appropriate treatment given. The authors of this case series reviewed the limitations/interference factors of HemosIL HS D-Dimer reagent, along with 2 other D-Dimer reagents and subsequently developed recommendations which may be useful in interpretation of D-Dimers in clinical practice. Additionally, recommendation for cautious interpretation of D-Dimer results in conjunction the Constans scoring tool with scores of 1 or less.

Corresponding Author:

Aaron Niblock, Haematology Department, Antrim Area Hospital, Northern Ireland; School of Medicine, Ulster University, Northern Ireland

Citation:

Andrew Ryan, Mark Ferguson, Mohammed Hassan, Aaron Niblock (2023). Diagnostic Challenge of d-dimer Negative Upper Extremity DVT. World J Case Rep Clin Imag. 2023 November-December; 2(2):1-6.

Copyrights

© 2023, Aaron Niblock, *et al.* This article is licensed under the Creative Commons Attribution-Non Commercial-4.0-International-License-(CCBY-NC) (<https://worldjournalofcasereports.org/bl ogpage/copyright-policy>). Usage and distribution for commercial purposes require written permission.

Background

Studies suggest D-Dimer has a high sensitivity with negative predictive value for upper extremity DVT (UEDVT). Sensitivity is around 92% with a negative predictive value of 98%. UEDVT is an uncommon presentation with an incidence rate of 4-10%. Overall DVT has an incidence of 1 per 1000 per year [1]. Risk factors for UEDVT include thrombophilia, central venous catheters, malignancy,

pacemakers and upper limb surgery and/or immobilisation. With or without these risk factors; Paget Schroetter Syndrome is a well-recognised form of UEDVT. Paget Schroetter Syndrome is thrombosis of the axillary and subclavian veins induced through mechanical effort compressing the subclavian vein at the thoracic outlet [2]. Though a 2 level Wells' Score is largely used for the assessment of lower limb DVT, use of scoring systems for assessing UEDVT risk is less well known and therefore poorly utilised [3].

A scoring system similar to a Wells' score, known as Constans score or Constans criteria, is a 2 level scoring system developed and first published in 2008. The Criteria considers, venous material *in-situ*, localised pain, unilateral oedema and plausibility of alternative cause. Score interpretation; -1 to 0 points (low probability of UEDVT

12%), 1 point (intermediate probability 20%), 2 to 3 points (high probability 70%) [4].

Kleinjan, *et al.*, sought further improved upon this scoring tool by incorporating D-dimer results in the stratification of intermediate risk patients, asserting that its use can safely and effectively exclude venous thrombosis of the upper extremity [8].

In both of the following cases presented the Constans score was 1 prompting the use of D-dimer to discriminate for probable UEDVT.

Case Presentation

Case 1:

Patient A; 46y/o female; no significant past medical history. Attended Assessment Unit with a four-day history of right arm swelling. Mild tenderness over forearm and upper arm were noticed with no obvious evidence of cellulitis. Superficial venous congestion around the shoulder was noted and the patient felt her axilla was more prominent. She denied breast lumps/masses. 2 weeks prior to presentation patient reported moving a wardrobe possibly provoking muscle injury in over chest wall and arm. ECG: NSR, rate 95 bpm. CXR unremarkable. FBP Normal. D-Dimer normal (159ng/ml) (Reference range 0-250ng/ml).

Patient was treated with therapeutic enoxaparin for probable DVT given lack of alternate diagnosis. Right upper limb US Doppler was performed the next day which confirmed thrombus in the right axillary vein extending into the right subclavian vein. CTPA was advised by reporting radiologist due to the extent of thrombus. This showed a small sub segmental PE in the right lower lobe. A mildly dilated ascending aorta (4.2cm) was also noted, though felt to be incidental.

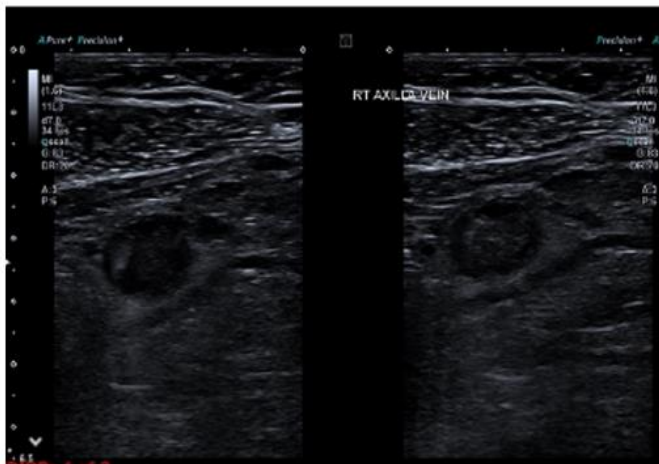


Image 1: Two Images of the right axillary vein with and without compression. The vein does not compress as its filled with echo bright clot.

She was commenced on warfarin therapy with bridging enoxaparin until INR was >2.0. Subsequent investigations including breast imaging, US abdomen and thrombophilia screen revealed no underlying pathology to account for the upper limb DVT.

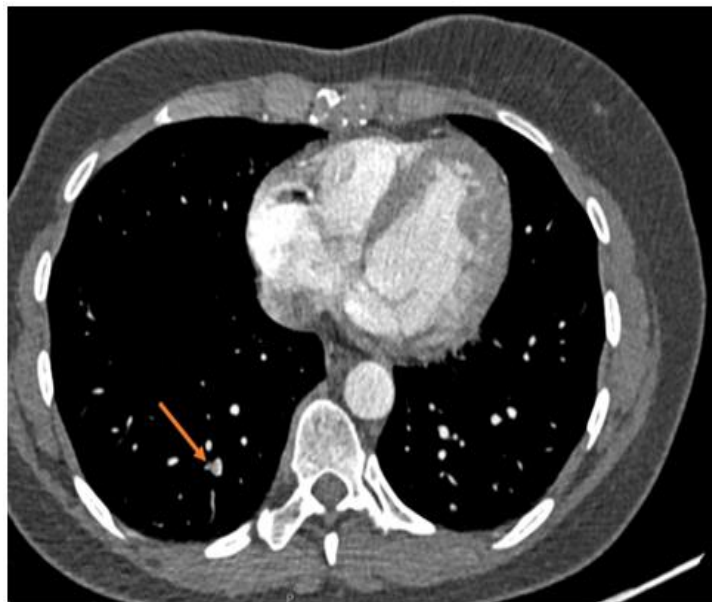

Image 2: Small thrombus at a sub-segmental artery supplying the artery of the poster-basal segment of the right lower lobe (orange arrow).

Case 2:

Patient B; 31y/o female; no significant past medical history. Attended Assessment Unit with a one week history of right sided upper arm pain and swelling. Her symptoms developed after exercise, initially as right shoulder and scapular pain before spreading to the upper arm the following day. Two days subsequent, the arm began to swell.

Clinical examination revealed an area of erythema over upper arm with evidence of venous distension. Associated tenderness on palpation of the medial aspect of the upper arm and mild reduction in shoulder range of movement. Patient was otherwise systemically well and denied weight loss. Routine blood tests including D-Dimer were normal. ECG: NSR with no tachycardia. Patient was given therapeutic enoxaparin for VTE in absence of alternate diagnosis. Right upper limb US Doppler performed the following day confirmed occlusive thrombus in the basilic, axillary and subclavian veins with patent internal jugular vein.

She was commenced on warfarin therapy with bridging enoxaparin until the INR was >2.0 CXR, breast examination and thrombophilia screen did not identify any contributable underlying pathology for development of VTE.

This case of upper limb thrombosis may also have been associated with strenuous exercise (Paget Schroetter Syndrome).

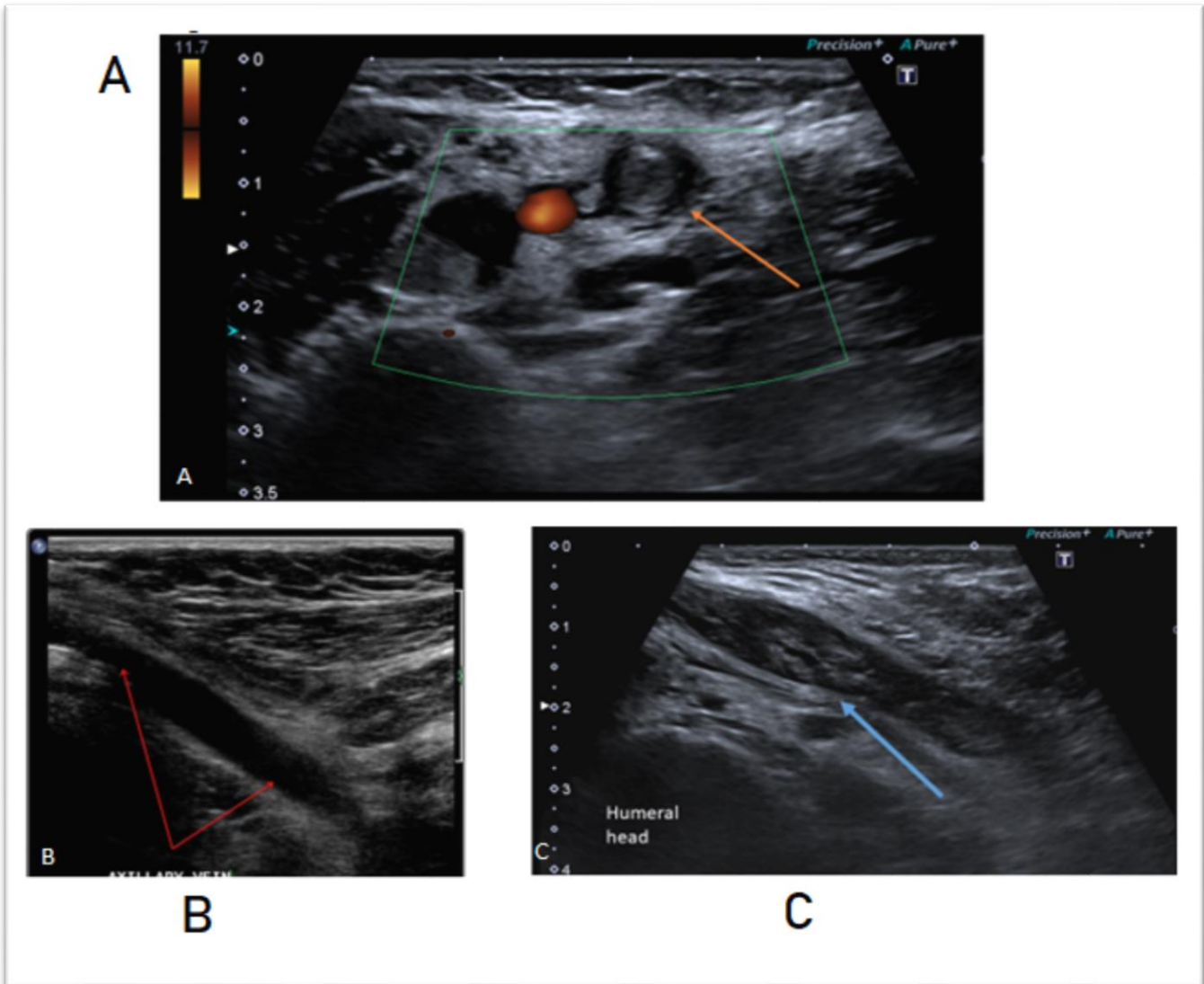


Image 3: (A) Doppler flow ultrasound of the right upper arm shows positive flow in the brachial artery (orange), this is flanked by two brachial veins with no flow. An echogenic focus can be seen occluding one of the veins (arrow typical of an upper limb DVT); (B) A picture of a normal axillary vein, note how fluid (blood) in the lumen is black on ultrasound (red arrows); (C) Longitudinal image of the right axillary, this again is completely showing echogenic material within the lumen (blue arrow).

Limitations of d-dimer Assays

Within our hospital the ACLTOP 750 CTS analyser is used. Produced by Werfen, it is capable of performing clotting screens, chromogenic and immunological assays.

Currently, the D-dimer reagent used is HemosIL D-Dimer HS. However, this is changing to HemosIL D-Dimer HS 500. Both these reagents are produced by Werfen, the only difference being the fibrinogen equivalence of the HS 500 reagent leading to different units/reference ranges in reporting. The regional coagulation laboratory use the STA® Liatest DDI PLUS reagent for the testing of D-Dimer using STAGO Compact Max 3 analyser.

D-dimers are soluble derivatives produced from degradation of cross linked fibrin clot by plasmin. Both HemosIL D-Dimer HS, and HemosIL D-Dimer HS 500 are latex reagents comprised of polystyrene particles uniformly coated with F(ab')₂ fragment from the monoclonal antibody MA-8D3 which is highly specific for D-dimer domains. The product literature asserts that the use of the F(ab')₂ fragment permits more specific identification of D-dimer and avoids interference with endogenous factors such as Rheumatoid factor [5,6]. The STA® DDI PLUS reagent is a similar product, with latex particles covalently bonded to a monoclonal antibody against D-Dimer [7].

Photometry is used to measure agglutination, and thereby D-Dimer levels for all of the reagents described.

The HemosIL literature also states limitations/potential inference factors which should be considered when interpreting D-dimer results. In the context of ACLTOP analysers being operated with the aforementioned HemosIL reagents; providing haemoglobin contamination is <500mg/dL, bilirubin <18mg/dL, triglycerides

<1327mg/dL, RF <1400UI/mL; and fibrinogen degradation products (FDPs) <10micrograms/mL, no interference with quantitative detection of D-Dimer ought to occur [5,6].

Additionally, both HemosIL reagents contain a buffer against Human Anti-murine Antibodies (HAMA), the presence of which may lead to over-estimation of D-Dimer levels [5,6]. Patients with HAMA will have previous exposure to mouse derived monoclonal antibodies (e.g. Bilantomab used in refractory ALL). Therefore, if a patient on immunotherapy has a D-Dimer performed which is elevated, due diligence should be undertaken to assess for potential HAMA and ensure appropriate management is given to the patient.

STA® DDI PLUS has similar limitations reported while also having a buffer for HAMA. Haemoglobin concentration ought to be <2g/L, conjugated and unconjugated bilirubin <29mg/dL and 20mg/dL respectively, RF <1000iU/mL and FDPs <15micrograms/mL. Similarly, cloudy plasma may lead to underestimation of D-dimer and significant presence of heparin/heparinoids leads to test insensitivity [7].

Conclusion

Traditionally D-Dimer is combined with a pre-test probability to rule out VTE, utilising the strong negative predictive value that D-Dimer assays offer. With relation to the Constans criteria; this case series confirms that the high negative predictive value of D-dimer results are not 100% reliable and caution ought to be used in utilising it this scoring tool.

In clinical practice D-Dimer negative VTE has a low occurrence. However, both these cases allude to the potential for UEDVT to be missed if significant weight is put upon D-Dimer levels in ruling out thrombosis where the Constans score is 1 or less. Such cases will be most commonly encountered by Emergency Medicine and Acute Medical teams.

With regard to the limitations/potential interference factors stated for HemosIL D-Dimer HS, HemosIL D-Dimer HS 500 and STA® Liatest DDI PLUS; in real terms the levels are to an extreme which is unlikely to be frequently encountered in clinical practice.

However, our recommendation is, (in hospital laboratories using these reagents) if incongruence is seen between the clinical presentation of probable VTE and a negative D-Dimer result, then an open mind should be given to potential assay interference. Such clinical scenarios could include, decompensated liver failure, rhabdomyolysis, and metabolic states with elevated lipids or acute flare of rheumatological disease with elevated serological markers.

Incongruent results should prompt discussion with local haematology/coagulation laboratory as to whether potential interference could be causing an inappropriate D-dimer reading. This may identify issues with sample acquisition in the clinical area or in sample preparation at lab level.

If concerns of inaccurate D-Dimer results are confirmed, then liaison with a laboratory using different coagulation analysers and reagents could be considered.

Conflicts of interest: There is no potential competing interests

Ethical Consideration: None

Acknowledgements: None

Références

1. Lim W, Le Gal G, Bates S, *et al.*, American Society of Hematology 2018 Guidelines for Management of Venous Thromboembolism: Diagnosis of Venous Thromboembolism. *Blood Adv.* 2018;2(22):3226-3256.
2. Patel P, Braun C, Patel P, *et al.*, Diagnosis of deep vein thrombosis of the upper extremity: a systematic review and meta-analysis of test accuracy. *Blood Adv.* 2020;4(11):2516-2522.
3. Wells PS, Anderson DR, Rodger M, *et al.*, Evaluation of D-dimer in the diagnosis of suspected deep-vein thrombosis. *N Engl J Med.* 2003;349(13):1227-1235
4. Constans J, Salmi LR, Sevestre-Pietri MA, *et al.*, A clinical prediction score for upper extremity deep venous thrombosis. *Thromb Haemost.* 2008;99(1):202-207.
5. Werfen. (2022). HemosIL D-Dimer HS 0020007700. Werfen. 712 The Quadrant, Cavendish Avenue: Werfen
6. Werfen. (2022). HemosIL D-Dimer HS 500 0020500100. Werfen. 712 The Quadrant, Cavendish Avenue: Werfen.
7. Diagnostica STAGO S.A.S. (2022). STA - Liatest D-DI PLUS. 2 allée theresa 92600 asnieres sure seine (France): Diagnostica STAGO.
8. Kleinjan A, Di Nisio M, *et al.*, Safety and feasibility of a diagnostic algorithm combining clinical probability, d-dimer testing, and ultrasonography for suspected upper extremity deep venous thrombosis: a prospective management study. *Annals of Internal Medicine.* 2014;160:451-7.

Submit your manuscript to the
World Journal of Case Reports and Clinical Images
(ISSN: 2835-1568; CODEN: USA)

and benefit from:

- Convenient online submission
- Rigorous peer review
- Immediate publication on acceptance
- Open access: articles freely available online
- High visibility within the field
- Retaining the copyright to your article

Submit your manuscript at
<https://worldjournalofcasereports.org/>

&
wjcasereports@gmail.com;
submission@worldjournalofcasereports.org

