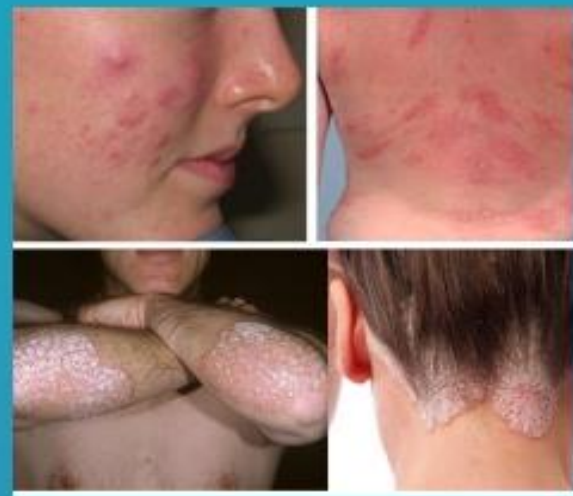
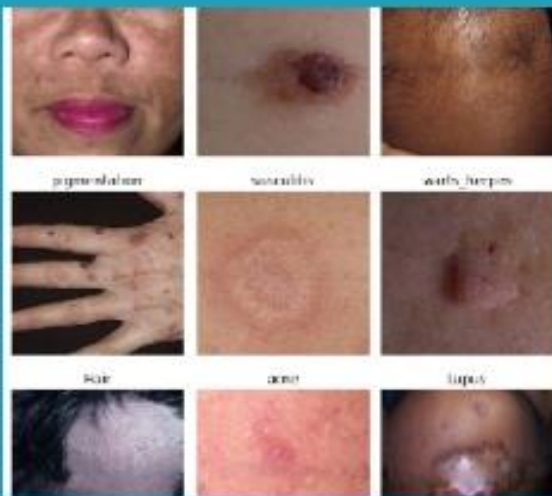
ISSN: 2835-1568 CODEN: USA DOI: 10.51521



WORLD JOURNAL OF CASE REPORTS & CLINICAL IMAGES

Advancing Cases



<https://worldjournalofcasereports.org/>



CASE REPORT

Intrathoracic Challenging Mass Ultrasonographic Video Presentation.

Emira Hysa.MD* Eugerta Dilka PhD**, Olvis Petre PhD*, Franc Rrumbullaku MD* Prof.Perlat Kapisyzi FCCP**

Received Date:
17-11-2023
Revised Date:
19-11-2023
Accepted Date:
22-11-2023
Published Date:
28-11-2023

*University Hospital "Shefqet Ndroqi" Tirana Albania

**University of Medicine Tirana Albania

Abstract

Background: The diagnostic value of lung ultrasound in identifying intra-thoracic masses following previous surgical interventions is shrouded in intrigue. Under-reporting and medico-legal concerns further complicate the identification and diagnosis of such cases. This study aims to unravel the enigmatic ultrasound characteristics of a unique intra-thoracic mass, accompanied by an enthralling ultrasound video presentation.

Case Report: In this captivating case, a 66-year-old patient, who had undergone aortic valve replacement surgery five years prior, presented for a routine check-up. An incidental hypo echoic image in the lung sparked further investigation. Imaging studies revealed a distinct round mass, and lung ultrasound provided intriguing insights into its features, including hypo echoic, hyper echoic density, posterior hyper echoic densities, and dynamic changes with probe manipulation. Surgical intervention uncovered a suppurated cystic formation and a retained surgical material from the previous procedure.

Conclusion: The unconventional nature of an intra-thoracic round mass following prior surgical intervention adds an aura of mystique to this case. Diagnosis and management are complex due to limited reported cases and medico-legal considerations. By sharing the captivating ultrasound characteristics and video presentation of this unique case, we aim to deepen our understanding of this enigmatic phenomenon and raise awareness among clinicians. This knowledge can aid in the timely identification and appropriate management of similar cases, ultimately improving patient outcomes. The diagnostic value of lung ultrasound in intra-thoracic masses should not be overlooked, offering a radiation-free approach to post-operative follow-up and the detection of late complications.

Keywords: Thoracic Ultrasound, Intrathoracic Mass, Gossypiboma

Corresponding Author:

Prof.Perlat Kapisyzi FCCP,
University of Medicine Tirana Albania

Citation:

Emira Hysa, Eugerta Dilka, Olvis Petre, Franc Rrumbullaku, Prof. Perlat Kapisyzi (2023). Intrathoracic Challenging Mass Ultrasonographic Video Presentation. World J Case Rep Clin Imag. 2023 November 2(2)1-4.

Copyrights

© 2023, Perlat Kapisyzi, et al. This article is licensed under the Creative Commons Attribution-Non-Commercial-4.0-International-License-(CCBY-NC) (<https://worldjournalofcasereports.org/blogpage/copyright-policy>). Usage and distribution for commercial purposes require written permission.

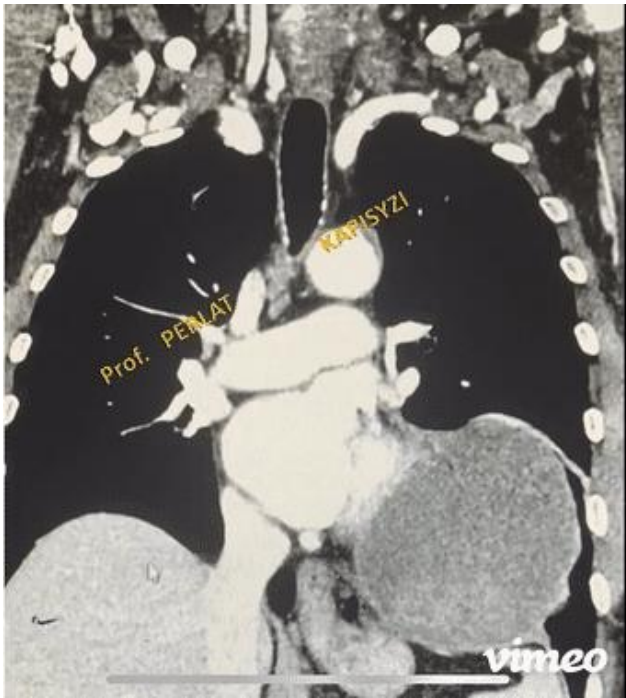
Introduction

Gossypiboma is a term used when gauze or other cotton materials are accidentally left behind during surgical interventions.

As doctors we are taught "When you hear hoof beats think horses not zebras" in our daily practice. However, this phrase sometimes has a negative impact by making us think only about the "horse" and neglecting the "zebra". Gossypiboma is a very rare diagnosis for two reasons: first, post-operative control procedures are followed carefully, and second, these cases are not often reported because of medical-legal reasons.

We are presenting ultrasound propedeutics of intra thoracic gossypiboma. During the searching in internet, we didn't find [ultrasound video](#) of intra thoracic gossypiboma. We are presenting by video ultrasound findings of intra thoracic gossypiboma.

Play the video by clicking on the below image



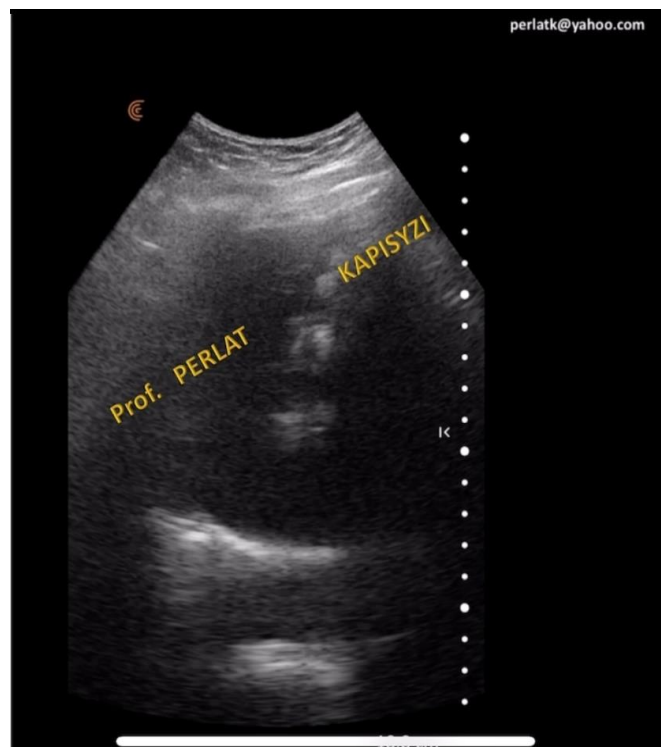
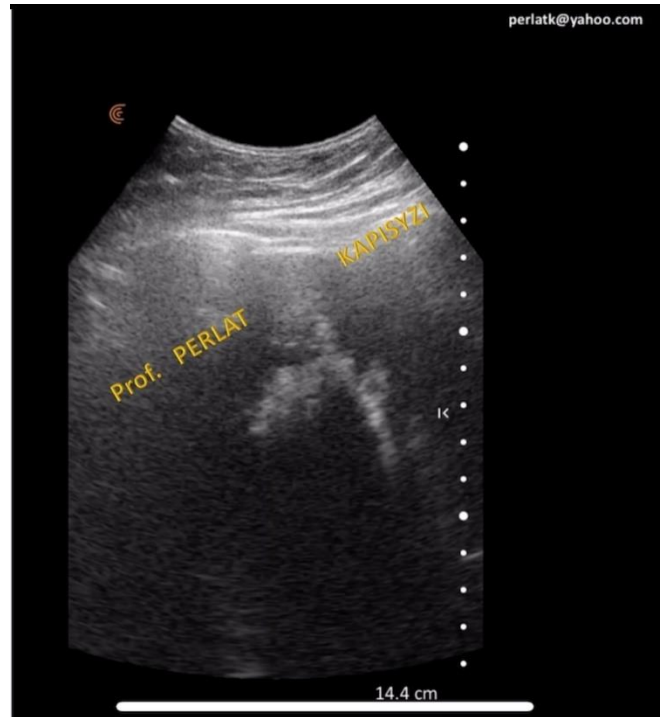Source: [Video Presentation](#)

Case Report

A 66-year-old patient presented to the cardiologist for routine check-up. The patient had undergone aortic valve replacement surgery 5 years ago. The patient had no pulmonary complaints. During the examination, the cardiologist observed a hypo echoic image in the lung and referred the patient to a pulmonologist. The patient's X-ray showed a homogenous increase in pulmonary density with clear contours a round shape near the para cardiac area.

The pulmonary CT scan revealed a round mass with dimensions of 106mm x 130mm x 112mm and a density ranging from 20 to 50 HU, which did not take contrast.

The lung ultrasound revealed a round hypo echoic density, strong posterior hyper echoic densities, with hyper-echoic longitudinal densities inside, which took on different shapes and densities when the axis of the probe was changed or during tilting maneuver. These hyper-echoic formations waved according to the heart rate.



Since the image did not exclude a liquid nature and the dimensions were more than 30 mm, the patient underwent surgical intervention rather than trans thoracic biopsy. During the surgical intervention, a suppurated cystic formation and a forgotten gauze were found from the surgery performed 5 years ago.

Discussion

Gossypiboma, derived from the Latin word ‘gossypium’ meaning cotton and Swahili word ‘boma’ meaning place of concealment, describes a retained non-absorbable surgical material composed of a cotton matrix [1]. Wilson reported the first case of gossypiboma in 1884. The actual incidence of gossypiboma is difficult to determine, as the condition is usually under-reported because of associated medico legal implications [2,3].

Two different types of pathological foreign body reactions can occur: a fibrinous response creating adhesions and encapsulation or an exudative process leading to abscess formation [4]. Incidence, ranges from 1 per 1000 to 1 per 10 000 cases [5].

In general, reported occurrences of thoracic gossypiboma are few, as cited in a 2014 review that noted not more than 40 cases documented in the English literature [6].

In the presented case, the CT did not clearly indicate the possibility of a foreign body in the thorax, although in some cases, CT can reveal hyper-densities that suggest a diagnosis of gossypiboma. In our case, retrospective thoracic ultrasound helped to identify foreign bodies inside the abscessed liquid formation. To our knowledge, this is the first case of intra-thoracic gossypiboma demonstrated with sonographic images.

However, the ultrasound propaedeutics of intra thoracic gossypiboma is the same as abdominal one: may appear as a well-defined mass containing wavy, bright, internal hyper echoic structure with a hypo echoic rim and a strong posterior hyper echoic densities [7,8].

The time from the surgery to diagnosis ranged from 3 weeks to 52 years [5,9]. Depending on the location and time, gossypiboma can present with signs of pulmonary infection. In the presented case, the patient had no pulmonary complaints, indicating that gossypiboma can remain asymptomatic for years and be discovered incidentally. Radiologic findings can be misdiagnosed as hematoma [10] bronchiectasis [11] malignancy [12] aspergilloma [13,14] hydatid cyst [15,16] and empyema [6].

Retrospectively, the CT showed a heterogeneous hyper-density with a posterior and declivity placement, simulating debridement in the declivity part of the abscess or echinococcus membrane. If the sponge doesn't contain radiopaque marker the CT diagnosis is not so easy. Irregular hyper density simulates popcorn images.

Whenever we diagnose an intrathoracic formation in a patient who has undergone surgical intervention, Gossypiboma should be included in the shortlist of differential diagnosis. Post-operative follow-up with thoracic ultrasound examination can be a new effective approach to detecting gossypiboma and late post-operative complications, avoiding radiation exposure through radiography or CT.

Conflict of Interest

There is Conflict of Interest

Ethical Consideration

None

References

1. Sozutek A, Karabuga T, Bozdag AD, et al. Asymptomatic gossypiboma mimicking a liver mass. *Turk J Surg.* 2010; 26:225–228.
2. Koul P, Mufti S, Khan U, Jan R. Intrathoracic gossypiboma causing intractable cough. *Interact Cardiovasc Thorac Surg.* 2012;14(2):228–30.
3. Seema Chopra, Vanita Suri, Pooja Sikka, Neelam Aggarwal: A Case Series on Gossypiboma - Varied Clinical Presentations and Their Management. *J Clin Diagn Res.* 2015 Dec;9(12)
4. Zantvoord Y, van der Weiden RM, van Hooff MH. Transmural migration of retained surgical sponges: a systematic review. *Obstet Gynecol Surv.* 2008;63:465–471.
5. Sharifah A Othman et al. Intrathoracic Gossypiboma: An Overlooked Entity *Am J Case Rep.* 2020.
6. Parra M, Oppliger F, Berríos R, Schiappacasse G. Intrathoracic gossypiboma presenting 52 years later as a chest mass. *Asian Cardiovasc Thorac Ann.* 2014;23(5):596–98
7. Chau WK, Lai KH, Lo KJ. Sonographic findings of intra-abdominal foreign bodies due to retained gauze. *Gastrointestinal Radiol* 1984; 9(1):61-63.
8. Shyung LR, Chang WH, Lin SC, et al. Report of gossypiboma from the standpoint in medicine and law. *World J Gastroenterol* 2005; 11:1248 –1249.
9. Gulsen A. Intrathoracic gossypiboma: 2 case reports and review of the literature. *JLPRR.* 2016;3:100.
10. M Coşkun et al. CT features of pericardial gossypidoma. *Eur Radiolog.* 199;9(4):728-730
11. T Suwatanapongched, et al. Intrathoracic gossypiboma: radiographic and CT findings. *Br J Radiol.* 2005.;78(933):851-853.
12. César García de Llanos, et al. Intrathoracic gossypiboma interpreted as bronchogenic carcinoma. Another false positive with positron emission tomography. *Arch Bronconeumol.* 2007;43(5):292-294.
13. H J Park, SA Im, HJ Chun. Changes in CT appearance of intrathoracic gossypiboma over 10 years *Br J Radiol.* 2008;81:e61-e63.
14. Ruquaya Mir, Singh VP. Retained intra- thoracic surgical pack mimicking as recurrent aspergilloma. *J Clin Diagn Res.* 2012;6(10):1775-1777.
15. Carlos Miguélez Vara, Marinar Gorospea M. Resected asymptomatic intrathoracic textiloma 37 years after thoracotomy. *Arch Bronconeumol.* 2010.;46(9):492-493.
16. A M Patel, VF Trastek, DT Coles. Gossypibomas mimicking echinococcal cyst disease of the lung. *Chest.* 1994;105(1):284-285.



Submit your manuscript to the
World Journal of Case Reports and Clinical Images
(ISSN: 2835-1568)

and benefit from:

- Convenient online submission
- Rigorous peer review
- Immediate publication on acceptance
- Open access: articles freely available online
- High visibility within the field
- Retaining the copyright to your article

Submit your manuscript at

<https://worldjournalofcasereports.org/>

&

wjcasereports@gmail.com;

submission@worldjournalofcasereports.org